

How to Improve Your Investigation and Prosecution of Strangulation Cases

By

Gael B. Strack, JD

Executive Director, National Family Justice Center Alliance

Prepared with the Assistance of Dr. George McClane,

October 1998, updated January 2003, and September 2007

The Prosecutor's Perspective

On a daily basis, police departments across the country receive a constant stream of 911 domestic violence calls where victims report being threatened, pushed, slapped, kicked, punched, choked, stabbed or even shot. Some agencies report that as much as 40 percent of all 911 calls are domestic violence related.

In March 1995, Casondra, a 17-year-old girl, made such a 911 emergency call to the San Diego Police Department. She reported being choked by her 21-year-old former boyfriend. Police were dispatched immediately and arrived at the scene within minutes. When the police arrived, the victim was recanting and her injuries were fading. Redness to the neck was all the officers could see. The suspect immediately claimed self-defense and the victim refused to give any additional statements. She emphatically begged for her former boyfriend to just leave her and her 18-month-old son alone! No arrest was made due to the lack of independent corroboration. However, the police dutifully took a report of the incident and submitted it to the Domestic Violence Unit of the San Diego Police Department for further investigation. The detectives followed-up with the victim and offered her referrals and information about domestic violence. The case was subsequently closed. A week later, her former boyfriend stabbed her to death in front of her stunned friends.

Six months later, Tamara, another teenager, died as a result of domestic violence. She was 16 years old, pregnant, and the mother of an 18-month-old girl. She was found dead in a dirt field, having been strangled to death and then set on fire by her 18-year-old former boyfriend.

The deaths of these two teenagers were shocking and a sobering reminder of the reality of teen relationship violence. The abrupt deaths of these two teenagers drove San Diego to action. It also drove San Diego City Attorney Casey Gwinn to study existing strangulation cases being prosecuted within his office. We learned that on a regular basis victims had reported being choked, and that in many of those cases, there was very little visible injury or evidence to corroborate the "choking" incident.

The lack of physical evidence caused the criminal justice system to treat many "choking" cases as minor incidents, much like a slap on the face where only redness may appear.

These two horrific deaths set San Diego on a course to learn as much as we could about

strangulation and improve our criminal justice response.

The Strangulation Study:

The study consisted of 300 strangulation cases, which were selected at random from police reports submitted over a five-year period. The victims were all women who reported being “choked” by their partners with bare hands, arms, or objects such as electrical cords, belts, rope, bras, or bathing suits. In one case, a victim reported that her boyfriend put a plastic bag over her head and tried to suffocate her.

There was a history of domestic violence in 89 percent of the cases, and children were present in at least 50 percent of the cases.

Focusing on the visible signs of strangulation, most victims lacked physical evidence of being strangled. They either had no visible injury (50%) or their injuries were too minor to photograph (35%). These minor injuries included redness on the neck and small cuts or scratches. See Figure 1.

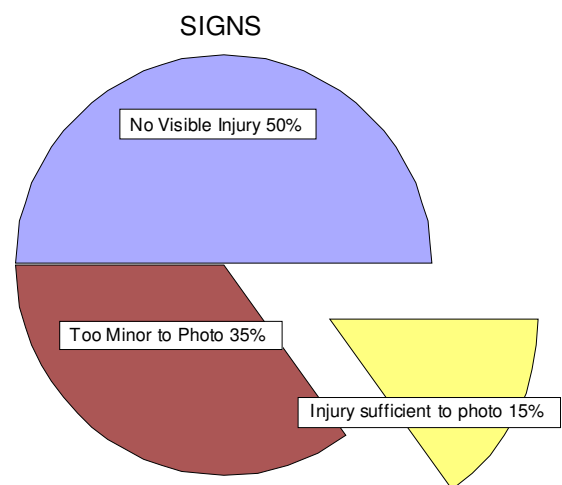
Visible injuries, such as red marks, bruises or rope burns, were found in 15 percent of the cases. While these injuries were significant enough to photograph, the majority of those photographs were unusable because they were blurry or washed out from the flash. This suggested a need for additional police officer training in close-up photography.

Victims sought medical attention in only 3 percent of the cases, primarily due to persistent pain, voice changes, or trouble swallowing.

Focusing on the symptoms, the study showed that police reports often neglected to clearly document what, if any, symptoms victims were experiencing. Leading to the conclusion that either the officers were failing to ask and/or the victims were failing to report their symptoms. When the report did mention a symptom, the study showed that victims often reported pain to their throats or hoarseness. Some victims reported nausea, loss of consciousness, hyperventilation, defecation, uncontrollable shaking, or loss of memory. In one case, the victim had a miscarriage within 24 hours of being strangled.

To understand the medical significance of the findings from the study, the City Attorney’s Office enlisted the help of Dr. George McClane, a local specialist on Emergency Room medicine

Figure 1



and Dr. Dean Hawley, a specialist in forensic pathology, for their medical perspective.

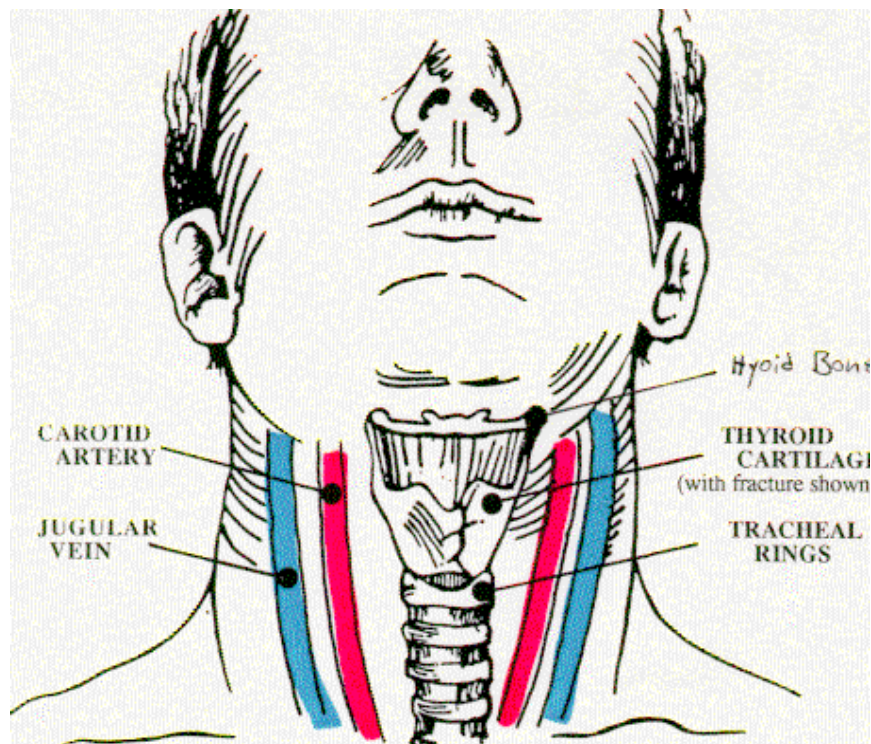
The Medical Perspective:

Strangulation is defined as a form of asphyxia (lack of oxygen) characterized by closure of the blood vessels and/or air passages of the neck as a result of external pressure on the neck.¹ The three forms of strangulation are hanging, ligature, and manual. Almost all attempted or actual homicides by strangulation involve either ligature or manual strangulation. Ten percent of violent deaths in the U.S. each year are due to strangulation, six females to every male.

Ligature strangulation is strangulation with a cord-like object (also referred to as garroting), and may include anything from a telephone cord to articles of clothing.² Manual strangulation (throttling) is usually done with the hands, but notable variants include using the forearms (as when police officers use the carotid restraint) to standing or kneeling on the victims throat.³ Manual self-strangulation is not possible, because when the individual loses consciousness, pressure can no longer be applied.

A rudimentary knowledge of neck anatomy is critical in order to understand adequately the clinical features of strangled victim. The hyoid bone a small horseshoe-shaped bone in the neck, helps to support the tongue. The larynx, made up of cartilage, not bone, consists of two parts: the thyroid cartilage (so-called because it is next to the thyroid gland) and the tracheal rings.

Carotid arteries are the major vessels that transport oxygenated blood from the heart and lungs to the brain. These are the arteries at the side of the neck that persons administering CPR (cardio-pulmonary resuscitation) check for pulses. Jugular veins are the major vessels that transport deoxygenated blood from the brain back to the heart.



The general clinical sequence of a victim who is being strangled is one of severe pain, followed by unconsciousness, then brain death. The victim will lose consciousness by any one or all of the following: blocking of the carotid arteries (depriving the brain of oxygen), blocking of the jugular veins (preventing deoxygenated blood from exiting the brain), and closing off the airway, causing the victim to be unable to breathe.

Only eleven pounds of pressure placed on both carotid arteries for ten seconds is necessary to cause unconsciousness.⁴ However, if pressure is released immediately, consciousness will be regained within ten seconds. To completely close off the trachea, three times as much pressure (33 lbs.) is required. Brain death will occur in 4 to 5 minutes, if strangulation persists.

Signs and symptoms

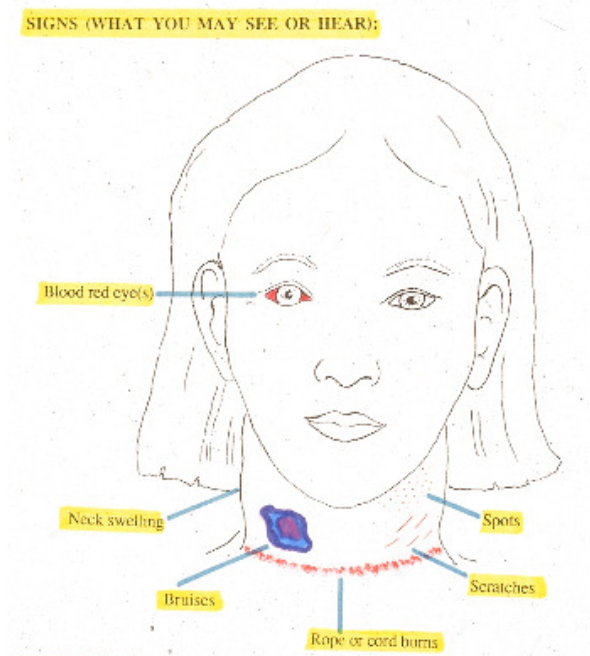
Symptomatic voice changes will occur in up to 50 percent of victims, and may be as mild as simple hoarseness (dysphonia) or as severe as complete loss of voice (aphonia).⁵

Swallowing changes are due to injury of the larynx cartilage and/or hyoid bone. Swallowing may be difficult but not painful (dysphagia) or painful (odynophagia). Breathing changes may be due to the hyperventilating that normally goes hand in hand with a terrifying event, but more significantly may be secondary to an underlying neck injury. The victim may find it difficult to breathe (dyspnea) or may be unable to breathe (apnea). It is critical to appreciate that although breathing changes may initially appear to be mild, underlying injuries may kill the victim up to 36 or more hours later due to decompensation of the injured structures.

Mental status changes may manifest early as restlessness and combativeness due to temporary brain anoxia and/or severe stress reaction, and subsequent resolve.⁶ Changes can also be long-term, resulting in frank psychosis and amnesia.

Objective signs noted in strangulation victims include involuntary urination and defecation. Miscarriages have been anecdotally reported occurring hours to days later.

Visible injuries to the neck include scratches, abrasions, and scrapes. These may be from the victim's own fingernails as a defensive maneuver, but commonly are a combination of lesions caused by both the victim and the



assailant's fingernails. Lesion location varies depending on whether the victim or assailant used one or two hands, and whether the assailant strangled the victim from the front or back.

Three types of fingernail markings may occur, singly or in combination: impression, scratch, or claw marks. Impression marks occur when the fingernails cut into the skin; they are shaped like commas or semi-circles. Scratch marks are superficial and long, and may be narrow or as wide as the fingernail itself. Claw marks occur when the skin is undermined; they tend to be more vicious and dramatic appearing.⁷ Because most victims are women, the scratches caused by their longer nails frequently are more severe than the scratches caused by assailant's. Claw marks may be grouped, parallel markings vertically down the front of the neck, but often are scattered in a random fashion.

Redness (erythema) on the neck may be fleeting, but may demonstrate a detectable pattern.⁸ These marks may or may not darken to become a bruise. Bruises (ecchymoses or purpura) may not appear for hours or even days. Fingertip bruises are circular and oval, and often faint. A single bruise on the neck is most frequently caused by the assailant's thumb.⁹ However, bruises frequently may run together, clustering at the sides of the neck, as well as along the jaw lines, and may extend onto the chin, and even the collar bones (clavicles).

Chin abrasions are also common in victims of manual strangulation, as the victim lowers the chin in an instinctive effort to protect the neck, and in so doing, scrapes the chin against the assailant's hands.

The tiny red spots (petechiae) characteristic of many cases of strangulation are due to ruptured capillaries—the smallest blood vessels in the body—and sometimes may be found only under the eyelids (conjunctivae).¹⁰ However, sometimes they may be found around the eyes in the peri-orbital region, anywhere on the face, and on the neck in and above the area of constriction. Petechiae tend to be most pronounced in ligature strangulation.¹¹ Sometimes victims present with florid petechiae which looks like a rash. Blood red eyes (subconjunctival hemorrhages) are due to capillary rupture in the white portion (sclera) of the eyes. This phenomenon suggests a particularly vigorous struggle between the victim and assailant.

Ligature marks (e.g., rope burns) may be very subtle, mimicking the natural folds of the neck. They may also be much more dramatic, reflecting the type of ligature used, e.g., the wave-like form of a telephone cord, or the braided pattern of a rope or clothesline. If the victim has been strangled from behind, the impression from the ligature generally will be horizontal at the same level of the neck. This may be of use to differentiate the ligature mark from strangulation from the pattern left from a hanging. In a hanging, the ligature mark tends to be vertical and teardrop shaped, with the knot at the nape of the neck, directly in front or behind the ear or up under the chin.¹² To further differentiate strangulation by ligature from strangulation by hanging, in ligature, the mark on the neck is usually below the level of the thyroid cartilage ("Adam's apple") while in hanging, it is usually above. Finally, in strangulation by ligature, the hyoid bone and/or thyroid cartilage are often fractured, in hanging, these are usually intact. Ligature marks are a clue that the hyoid bone may be broken. As a general rule, on a post mortem exam, if a hyoid bone is fractured the death will be a homicide from strangulation until

proven otherwise.¹³ However, because the two halves of the hyoid do not fuse until age 30, the hyoid may not break in younger victims who die as the result of strangulation.¹⁴ One third of manual strangulation victims have fractured hyoids.¹⁵

Swelling (edema) of the neck may be caused by any one or combination of the following: internal bleeding (hemorrhage),¹⁶ injury of any of the underlying neck structures, or fracture of the larynx allowing air to escape into the tissues of the neck (subcutaneous emphysema).

Lung damage may be due to vomit inhaled by the victim during strangulation.¹⁷ This may lead to aspiration pneumonitis—a very serious condition as the gastric acids begin to digest the lung tissue. Milder cases of pneumonia may also occur hours or days later.¹⁸ The lungs may also fill with fluid (pulmonary edema) due to complex pathological processes that may arise from direct pressure placed on the neck.

Last, victims may have no visible injuries whatsoever, with only transient symptoms —yet because of underlying brain damage by lack of oxygen during the strangling, victims have died up to several weeks later.¹⁹ Because of these unforeseen consequences of injuries from a strangulation attempt that may appear minor to the untrained, officers at the scene should radio for medics for a medical evaluation of all victims who report being strangled.

The Training Curriculum:

Realizing that untrained officers and prosecutors may fail to recognize the seriousness of attempted strangulation when victims survive, we developed training to assist professionals to identify the signs and symptoms common in strangulation cases.

Thanks to the input and contributions of many individuals,²⁰ such as detectives, prosecutors and physicians, we suggest considering the following practical tips:

PRACTICAL TIPS

1. Treat your Strangulation Cases Seriously

Start by changing your vocabulary and using words such as strangle, attempted strangulation, near-fatal strangulation and/or strangulation when the victim reports to you that she was “choked.” Strangle means to obstruct seriously or fatally the normal breathing of a person. Choke means having the windpipe blocked entirely or partly by some foreign object like food.

Once a victim reports being strangled, treat the case as a felony. If there is evidence to suggest the victim was strangled and her life was threatened, the case should be considered and investigated as if it were an attempted homicide or aggravated assault case. If you treat the case

seriously from the time the 911 call is made, so will everyone else, including the victim. Most states have aggravated assault crimes. In California, it is appropriate to charge a defendant with felony assault under Penal Code section 245(a) when it is shown that the defendant had the intent to commit great bodily injury – even if the victim only has redness on her neck or pain to her throat.²¹ It is also appropriate to arrest a suspect for attempted felony spousal abuse under Penal Code section 273.5.²² Currently, over 10 states have now passed strangulation laws in order to bring more awareness to the lethality of strangulation, to hold defendants accountable for the crimes they commit and to enhance victim safety. Those states (in alphabetical order) are: Alaska, Florida, Hawaii, Idaho, Louisiana, Minnesota, Missouri, North Carolina and Washington.

2. Conduct a Thorough Interview and Investigation at the Scene.

As discussed above, there are many ways a perpetrator can strangle a victim. The level of injuries and symptoms will depend on many different factors including the method of strangulation: the age and health of the victim, whether the victim struggled to break free, whether the victim was under the influence of alcohol and/or drugs, the size and weight of the perpetrator, the amount of force used, etc. And, in most cases, there will be no visible injuries at all. Therefore, it is important to ask the victim a series of follow-up questions that are designed to elicit specific information about her symptoms and internal injuries which are consistent with someone being strangled.

3. Use Follow-up Questions:

For Method and/or Manner:

- Ask the victim to describe how s/he was strangled. (One or two hands? Forearm? Object? Straddled? Pinned or banged against wall?)
- Document her description and the points of contact.
- Ask the victim to demonstrate how she was strangled. This can be done in a number of ways, such as, asking the victim to demonstrate how she was strangled, consider using a mannequin head for wigs for the victim to use to demonstrate how s/he was strangled. This method will avoid anyone applying any additional pressure to the victim's neck. Another method is by reenacting the incident. Caution should be taken to not reapply any pressure to the victim's neck or even to use the victim in this reenactment and it may re-traumatize the victim by having to relive the incident.
- Ask where the victim was strangled? (E.g. If bedroom, look for corroborating evidence).
- How long did the suspect strangle the victim?
- How many times and how many different methods were used to strangle the victim during this incident?
- How long did everything last from the point the argument started until the violence stopped?
- On a scale from one to ten, ten being the most pressure, how hard was the suspect's grip?
- On a scale from one to ten, ten being the most painful, how much pain was caused to the

victim?

For Identifying Visible Injuries:

- Look for injuries behind the ears, around the face, neck, scalp, chin, inside the mouth, jaw, on and under the eyelids, shoulders and chest area.
- Look for redness, scratch marks, scrapes, finger-print marks, thumb-print bruising, ligature marks, bruising, tiny red spots, swelling and/or lumps on the neck.
- If the victim is wearing makeup, ask the victim to remove makeup before you leave the scene. Take photographs before and after the make was removed. The first photo will show exactly what you saw and the second may capture additional injuries such as florid petechiae.
- Look for neck swelling. Neck swelling may be harder to detect. For neck swelling, ask victim to look in the mirror to assess any swelling. Take photos of the neck even if you do not see injuries nor swelling. They will likely appear later.

For Evidence Gathering:

- Does the victim have any pain? Where? (To document injuries under the skin, take ultra violet or infra-red photographs; alternatively, consider taking follow up photographs).
- Ask victim about injuries to head or injuries hidden by clothing.
- Was an object was used to strangle the victim? (locate, photograph, and impound the object).
- Was any property damaged ? (Dry wall damaged from victim's head?).
- Any medical treatment recommended or obtained? Obtain medical/dental release.

For Identifying Symptoms and Signs for Internal Injury:

- Was the victim shaken simultaneously while being strangled? (Possible whiplash)
- Was the victim thrown against the wall, floor, or ground ? (Possible concussion).
- Did the victim have difficulty breathing or appear to be hyperventilating?
- Any complaint of pain to the throat?
- Any trouble swallowing?
- Any drooling?
- Any voice changes, such as a complaint of a hoarse, raspy voice or loss of voice?
- Any coughing?
- Did the victim feel dizzy, faint, or lose consciousness?
- Did the victim, urinate or defecate as a result of being strangled?
- Does the victim's neck look swollen?
- Was the victim pregnant at the time?
- Did the victim feel nauseated or vomit?

For Establishing Motive, Intent and Anticipating Minimization/Recantation:

- What did the suspect say when he was strangling the victim? Use quotes.

- Ask the victim to describe the suspect's demeanor and facial expression.
- If an object was used, determine if the suspect brought the object to the crime scene. (This information may be used to show premeditation).
- What did the victim think was going to happen? (Did she think she was going to die?)
- What caused the suspect to stop? (Did she pass out? Witness(s) intervene?)
- Any prior incidents of strangulation? Any prior incidents of domestic violence?

To Eliminate defenses/excuses (self-inflicted injury, self defense, prior injury) :

- Did the victim attempt to use self defense, defense of others?
- Did the victim attempt to pry the suspects hands, fingers, arms and/or elbow away from self?
- Any injuries to the suspect, such as on the face, neck, arms, hands?
- Take photos of suspect – especially if no injuries.
- Any pre-existing injuries?
- Any recent surgery?

It is further recommended that officers, detectives, prosecutors and advocates working with victims of strangulation, educate victims about the seriousness of strangulation as well as the signs and symptoms of strangulation. Victims should also be encouraged to document and log their signs and symptoms.

As indicated above, this article focuses on attempted strangulation cases. For an excellent article on investigating homicide strangulation cases, “*A Guide to the Physical Analysis of Ligature Patterns in Homicide Investigations*” by Brent E. Turvey, MS, Winter, 1996. He can be reached for comment or consultation by contacting: Knowledge Solutions, 1271 Washington Avenue #274, San Leandro, CA 94577-3646. Phone 510-483-6739.

1. Look for Injuries

The victim may be embarrassed or minimize the incident. Look for injuries around the eyes, under the eyelids, nose, ears, mouth, neck, shoulders, and upper chest area. If injuries are present, look for redness, scratches, red marks, swelling, bruising, or tiny red spots (petechiae) that arise from increased venous pressure.²³

2. Take Plenty of Photographs and Follow-up Photographs

Take the following photographs:

- **Distance photo** - one full body photograph of the victim from a distance will help identify the victim and the location of the injury.
- **Close-up photo(s)** - multiple close-up photographs of the face, neck area (front, back, and sides of the neck) at different angles will make it easier to see the injuries clearly.

- **Follow-up photos** - taking follow-up photographs of the injury 24, 48 and 72 hours later will document the injuries as they evolve over time and maximize your documentation. It is also helpful to place a non-glare ruler in the same plane of the injury to accurately measure the size of the injury or injuries.

Most agencies are now using digital photography, some still take Polaroid or 35 mm photographs. In 1996, thanks to the support from Polaroid, 1600 Law Enforcement Camera Kits were purchased by police officers and sheriff deputies at dramatic savings. With the training Polaroid provided on close-up photography, we saw immediate improvement in the quality of photographs being taken by officers and an increase of prosecution involving attempted strangulation cases.

Some agencies use infrared and ultraviolet photography to document strangulation injuries. Infrared images can detect unseen bleeding below the skin surface, particularly in dark-skinned victim. Ultraviolet photography renders fine surface detail and can discover subtle injuries. Ultraviolet can also record old, completely invisible healed injuries. These techniques are used by Lt. James O. Pex, Oregon State Police, Coos Bay Forensic Laboratory, and Dr. Mike West, DDS, Coroner and Chief Medical Examiner Investigator, Forrest County Mississippi. Lt. Pex uses four photographic techniques in domestic violence cases: color photography, alternative light source (narrow band light source) photography, reflective ultraviolet (UV) photography, and infrared (IR) photography. Forensic Nurse Tara Henry from Alaska utilizes the colposcope to document strangulation injuries.

6. Take care to Identify the Dominant Aggressor.

Frequently, in attempted strangulation cases there are claims of mutual combat or self-inflicted injuries. Because victims fear for their lives, they may protect themselves by pushing, biting, scratching, or pulling their hair. Depending on the method of strangulation being used, the suspect may be the only individual with visible injuries.

For example, if the suspect is strangling the victim from behind and using a chokehold, the victim may protect herself by biting the suspect in the arm.

If the suspect is manually strangling the victim from the front (face to face), she may either push him away, scratch him, or pull his hair.

When officers arrive at the scene, they may find the suspect with visible injuries and the victim with no visible injuries. To identify the dominant aggressor, officers and prosecutors should consider the following factors:

1. Height/weight of the parties.
2. Who is fearful of whom.

3. Detail of statement and corroboration.
4. History of domestic violence, assaults, or criminal history.
5. Use of alcohol or drugs.
6. Whether either party is subject to a restraining order or on domestic violence probation.
7. Pattern evidence.
8. Injuries consistent with reported statement.
9. Examine hands for any hair, blood, fiber, or evidence of epithelia cells after strangulation (fingernail scrapings).
10. Signs of symptoms of strangulation.
11. Offensive/defensive injuries.

7. Encourage the Victim to Seek Medical Attention

As discussed above, there may be internal injuries to the victim that may later cause complete obstruction, even 36 hours after an injury.²⁴ As such, when victims report they were “choked,” dispatchers, patrol officers, investigators and prosecutors should strongly encourage victims to seek medical attention. If victims report symptoms such as difficulty breathing or swallowing, paramedics should be immediately dispatched to scene in order to screen the victim for possible internal injuries. Even if the paramedics determine a lack of objective symptoms to support internal injury, their medical examination will prove very helpful to assess her health and to document the victim’s visible injuries and/or symptoms. Without question, medical documentation is persuasive evidence. In one case prosecuted by the City Attorney’s Office in San Diego, the police officer indicated in his police report that the victim had “red abrasions to the neck.” He encouraged the victim seek medical attention which she did. In reviewing the medical records, the treating physician indicated the patient “had multiple linear contusions to both sides of her neck with overlying redness, mild edema and tenderness.” The medical corroboration tremendously enhanced the case, allowing the prosecutor to obtain a quick guilty plea in court. None of the witnesses nor the victim had to come to court to testify.

More importantly, by calling the paramedics, you may even save a life by providing the victim with immediate medical attention. It is better to be safe than sorry.

8. Note Your Experience in Your Report

As in other criminal cases, such as driving under the influence or being under the influence of a

control substance, patrol officers should note their experience and training concerning domestic violence and strangulation in their police report.

For example: “I have been a patrol officer for five years. During that time, I have investigated 500 domestic violence cases. In many of those cases, victims have reported being strangled. I have also received training in domestic violence and in particular the medical signs and symptoms of strangulation. Based on my experience and training, I know strangulation can cause serious injury. Unconsciousness can occur within seconds. Death can occur within minutes. The symptoms and injuries as reflected in this investigation are consistent with someone being strangled. The elements of a felony (list crime) are present. I further encouraged the victim to seek medical attention and to carefully log her symptoms and injuries.”

9. Obtain copies of your 911 Tapes

Because at least 50 percent of strangulation victims experience voice changes, it is important to obtain a copy of the 911 tape. If the victim called 911 to report the incident, you may have evidence of her voice changes.

10. Tape Record Your Follow-up Investigations

As mentioned above, voice changes will occur in up to 50 percent of victims. Anecdotally reported by San Diego Police detectives, voice changes may occur in as many as 80% of cases where victims report being strangled. Based on this anecdotal evidence and the medical literature, it is important to tape record or video tape your follow-up investigation to document voice changes for later evaluation by your medical experts and corroborate the victim’s allegations. Many digital cameras today also have a video feature, use the video feature to capture a raspy voice, difficulty swallowing, coughing, pain exhibited by the victim and/or drooling.

11. Use Forensic Investigators and/or Nurses

Forensic investigators and nurses are specially trained to gather evidence using various techniques and photographic equipment. They are proficient in follow-up examinations, taking photographs, and interpreting medical records. Since 1997, the San Diego City Attorney’s office has closely worked with forensic nurses to interpret medical records, distinguish between offensive and defensive injuries, distinguish between accidental and intentional injuries, document follow up injuries and/or to use in court as experts.

12. Use an Expert Witness at Trial

Even when the victim has not obtained medical treatment, it is important to use medical experts at trial in order to educate the jury and the judge about the seriousness of strangulation. Jurors and judges need to know that strangulation can cause unconsciousness within seconds²⁵ and death within minutes.²⁶ They also need to understand why symptoms are as important in the

prosecution of a strangulation case.²⁷

Expert testimony is admissible on a “subject that is sufficiently beyond common experience that the opinion of an expert would assist the trier of fact.” California Evidence Code section 801.

Expert witnesses can be used for various reasons, including teaching the jurors about medical, technical, or scientific principles or expressing an opinion after evaluating the significance of the facts of the case. Ultimately the judge will decide whether a witness is qualified to express an opinion on a strangulation case.

It is recommended that prosecutors use medical experts such as a coroner, medical examiner, emergency room physician, forensic nurse or a paramedic who has been trained and experience handling strangulation cases. Forensic nurses make particularly good witnesses because of their medical background, experience in evaluating patients and documenting evidence.

Prosecutors should also consider using police officers or investigators who have been trained in strangulation and have applied their training to strangulation cases they have investigated. In June 2000, Judge Bonnie Dumanis allowed Detective Mike Gulyas to testify in a misdemeanor attempted strangulation case after the foundation was laid that he had received special training and had expertise in responding to domestic violence cases involving strangulation. His testimony was based on his training and experience. Detective Gulyas had received training on strangulation in 1996. Since 1996, he applied the training he had received to the cases he investigated involving attempted strangulation. The case resulted in a guilty verdict and was upheld on appeal.

To establish the qualifications of your expert, consider the following areas of examination

1. Education
2. Training
3. Licenses and certificates
4. Work experience
5. Teaching experience
6. Published writings
7. Professional organizations
8. Previously qualified as an expert witness.

Below are some questions you may consider asking an emergency room physician in an attempted strangulation case:

1. Have you had the opportunity to examine patients who have reported being strangled?
2. Have you received training in strangulation?
3. Have you previously testified in court as an expert concerning strangulation?
4. Please define strangulation.
5. Please define asphyxia.
6. Are you familiar with the methods of strangulation?

7. Are you familiar with the signs and symptoms of strangulation?
8. Would a chart or charts help you explain those signs and symptoms?
9. Please describe the signs? The symptoms?
10. How does death occur from manual strangulation?
11. How many seconds would it take to lose consciousness from strangulation?
12. How many minutes would it take to manually strangle someone to death?
13. Is it possible to strangle someone to death without leaving any marks?
14. Are you familiar with the injuries and symptoms of this case? Describe.
15. Have you had the opportunity to review the police report, 911 tape, paramedic and medical records?
16. In your opinion, are the signs and symptoms in this case consistent with strangulation?
17. Is it your opinion that the application of force to the victim's neck for * seconds could cause internal injury? Could cause great bodily injury?

Below are questions for you may consider asking in a homicide by strangulation case (courtesy of San Diego County Deputy District Attorney Dan Goldstein):

1. Are you a medical examiner?
2. How long have you been a medical examiner?
3. What specific training goes into becoming a medical examiner?
4. What are your duties?
5. What is an autopsy?
6. How many autopsies have you conducted in your career?
7. Have you testified in court?
8. What is a witnessing pathologist?
9. Were you the witnessing pathologist on *** during an autopsy of the victim?
10. Who was the pathologist?
11. Did you review the pathologist's report?
12. Please describe the external trauma of the victim that you saw.
13. Ask the witness to describe photos and injuries.
14. Ask the witness to describe any injuries to the eyes, face, and mouth.
15. Ask the witness to describe internal injuries.
16. What was the cause of death?
17. What are the reasons you believe the victim died from strangulation?

Conclusion:

Today, we know that strangulation is one of the most lethal forms of domestic violence: **unconsciousness may occur within seconds and death within minutes.** Victims may have no visible injuries whatsoever —yet because of underlying brain damage by lack of oxygen during the strangling — victims may have serious internal injuries or die days or several weeks later. When domestic violence perpetrators use strangulation to silence their victims, not only is this felonious assault, it can be an attempted homicide. Strangulation is also a form of power and

control which can have a devastating psychological effect on victims in addition to a potentially fatal outcome.

The tragic deaths of 17 year-old Casondra Steward and 16 year-old Tamara Smith have lead to dramatic changes in San Diego. We developed a medical partnership with Dr. George McClane in late 1995. This legal-medical partnership lead to a training curriculum in 1996. The training lead to a better understanding of how to investigate and prosecute cases and protocols were updated and revised in 1998. The training is now helping thousands of domestic violence professionals across the country improve their investigation, documentation and prosecution of attempted strangulation cases. And wonderful things are happening:

- Many strangulation cases are being elevated to felony level prosecution due to the risk of death during the violence.
- Cases we once thought could not be prosecuted are being routinely submitted for either felony or misdemeanor prosecution.
- Law Enforcement and Prosecution Protocols are being updated.
- Specialized medical forms are being developed to help medical professional document injuries and identify symptoms (Diane Faugno from Pomerado Hospital).
- Both the California District Attorney's Office and the National College of District Attorney's Association took the lead in including strangulation in their conferences.
- Legislation has been passed to facilitate the prosecution of strangulation.
- District Attorney Penny Clute from Plattsburgh, New York launched a statewide campaign to educate law enforcement and medical professionals about strangulation (www.daclute.com).
- Detective Tom McNeal from Los Angeles Sheriff's Department trained over 3,000 officers on strangulation.
- Training tapes on strangulation have been developed by Law Enforcement Television Network, San Jose Police Department, the California Commission on Police Officers Standards and Training; and IMO Productions. These training tapes are being used to educate domestic violence professionals and even grand juries.
- Research is being conducted by Dr. Taliaferro and her team of medical students in Texas to learn more about the signs and symptoms of victims who survive attempted strangulation.
- Doctors, forensic nurses and domestic violence detectives are being developed as experts and are testifying in court about strangulation.
- Inspired by the strangulation articles published by the Journal of Emergency Medical in October 2001, many professionals are conducting their own studies and reporting on their similar findings.

If Casondra's and Tamara's cases have caused this wonderful progress and will motivate others to improve their investigation and prosecution of strangulation cases, then Casondra Steward and Tamara Smith did not die in vain.

For further information, contact Gael Strack, JD at gaelstrack@yahoo.com

References:

-
1. *Strangulation: a full spectrum of blunt neck trauma.* Ann Otol Rhinol Laryngol. 94: 6:1, Nov. 1985, 542-46. *Strangulation: a review of ligature, manual, and postural neck compression injuries.* Annotated Emergency Medicine, 13:3, March 1984, 179-85. K.V. Iserson.
 2. *Suicidal Garroting and Manual Self-Strangulation.* Journal of Forensic Science. 15:1, Jan. 1979. Joseph C. Rupp., M.D., Ph.D. *Throat-skeleton fractured by strangulation.* Z Rechtsmed. 79:2, March 23, 1977, 143-47. C.F. Hansch.
 3. *Hanging and manual strangulation.* Med. Science Law. 6:1, Jan. 1966, 49-51. F.D. Hocking. *A study of fatal strangulation cases in Varanasi (India).* American Journal of Forensic Medicine and Pathology, 8:3, Sept. 1987, 220-24. A.K. Srivastava, S.M. Das Gupta, C.B. Tripathi.
 4. *Correlation of Circumstances with Pathological Findings in Asphyxial Deaths by Hanging: A Prospective Study of 61 Cases from Seattle, WA,* Journal of Forensic Sciences, JFSCA, 30:4, Oct. 1985, 1140-47.
 5. *Manual Stragulation Injuries of the Larynx.* Arch. Otolaryngol. Vol. 109, May 1983, 344-47. Robert B. Stanley, Jr., M.D., D.D.S., David G. Hanson, M.D.
 6. *Strangulation Injuries in Children.* The Journal of Trauma: Injury, Infections & Critical Care. 40:1, Jan. 1996, 68-72.
 7. *Identification of fingernail markings in manual strangulation.* American Journal of Forensic Medicine and Pathology. 2:1, March 1981, 45-48. J.A. Perper, Michael N. Sobel, D.M.D. *Procedure in identifying fingernail imprint in human skin survives appellate review.* American Journal of Forensic Medicine and Pathology, 6:2, June 1985, 171-73. *Types of injuries and interrelated conditions of victims and assailants in attempted and homicidal strangulation.* Forensic Science International, vol. 18, 1981, 101-23.
 8. *Homicidal Manual Strangulation and Multiple Stun-Gun Injuries.* American Journal of Forensic Medicine and Pathology, 13:4, 1992, 32-23. Noriaki Ikeda, M.D., Akira Harada, B.S., and Tsuneo Suzuki, M.D.
 9. *Face and neck injuries due to resuscitation versus throttling.* Forensic Science International, vol. 23, 1983, 109-15. Teet Harm and Jovan Rajs.
 10. *Petechial Hemorrhages: A Review of Pathogenesis.* The American Journal of Forensic Medicine and Pathology. 15:3, Sept. 1994, 203-07. F.A. Jaffe.
 11. *Strangulation as a Method of Homicide.* Arch Pat. Vol. 83, Jan. 1967, 64-70. James. L. Luke, M.D.

-
12. *Asphyxia*. *Medicolegal Investigation of Death*. 11: 444-97. Werner U. Spitz. *Forensic Problems in Practice*, *Asphyxia*. *The Practitioner*. 217: 7, 139-44. Bernard Knight.
13. *The location of Hyoid Fractures in Strangulation Revealed by Xeroradiography*. *Journal of Forensic Sciences*. 1994, 303-305. Michael S. Pollanen, Barbara Bulger, R.T.(R), and David A. Chiasson, M.D.
14. *Age and ossification of the hyoid bone: forensic implication*. *Journal of Forensic Sciences*, 32:6, Nov. 1987, 1655-59. R.L. O'Halloran, J.K. Lundy.
15. *Hyoid fracture and strangulation*. *Journal of Forensic Sciences*, 37:5, Sept. 1992, 1216-22. D.H. Ubelaker.
16. *Mucosal hemorrhage of the larynx in strangulation and other causes of death*. *Beitr Gerichtl Med.*, 47: 429-435, 1989. H. Maxeiner, German. *Manual strangulation injuries of the larynx*. *Arch Otolaryngol*, 109:5, May 1983, 344-47. R.B. Stanley, Jr. *Injuries of the larynx*. *Probl. Actuels Otorhinolaryngol*. 1965, 133-44. J. Gardel, French.
17. *Aspiration of gastric contents in hanging with typical position of the strangulation cord suspension*. *Arch Kriminol*, 190:3-4, Sept. 1992, 97-102. M.A. Rothschild, German.
18. *The value of various lung changes in death by strangulation*. *Arch Kriminol*. 196:1-2, July 1995, 38-45. W. Grellner, German. *Animal experiment studies of acute emphysema caused by strangulation*. *Beitr Gerichtl Med.*, 1982, 40:123-28. J. Nasemann, German. *Mechanisms of the pulmonary congestion in ligature strangulation*. *Igaku Kenkyu*, Nov. 1989, 59:3, 97-98. Kita T. Furuya Y. *Japanese. Pulmonary tissues in strangulation*. *Igaku Kenkyu*, Feb. 1983, 53:1, 19-22. Y. Furuya, K. Shintaku, T. Kita.
19. *Delayed death following strangulation*. *Arch Kriminol*, Nov. 1987, 180:5-6, 161-71. H. Maxeiner. *A case of hypoxic brain damage consequent to ligature strangulation*. *Nippon Holgaku Zasshi*, April 1989, 43:2, 186-90. S. Kubo, M. Ogata, M. Iwasaki, O. Kitamura, I. Shimokawa, H. Suyama, M. Hironaka. *On the absence of cutaneous lesions of the neck in cases of strangulation*. *Minerva Medicoleg*, Nov. 1967, 87:6, 299-302. F. Nathan, Italian. *Case report. Delayed death after pressure on the neck: possible causal mechanisms for mode of death in manual strangulation discussed*. *Forensic Science Int.*, April 23, 1996, 78:3, 193-97. A.M. Anscombe. *Late neuropathological consequences of strangulation*. *Resuscitations*, Sept. 1987, 15:3, 171-85. R.K. Simpson, Jr., J.C. Goodman, E. Rouah, N. Caraway, D.S. Baskin. *Strangulation as a Method of Homicide*. *Arch Path*, vol. 83, January 1967, 64-70. James L. Luke, M.D.
20. Special thanks to San Diego City Attorney Casey Gwinn and Police Chief Jerry Sanders for authorizing this research and providing ongoing, year-round training to San Diego police officers and deputy city attorneys and the following individuals for contributing to the training

curriculum: Detectives at the the San Diego Police Department Domestic Violence Unit, Retired Police Sgt. Anne O'Dell, Nashville Police Sgt. Mark Wynn, San Diego Deputy District Attorney Dan Goldstein, Dr. George McClane, Dr. Dean Hawley, Dr. Ellen Taliaferro, San Diego Chief Medical Examiner Brian Blackbourne, Forensic Nurse Maggie Whelen and Oregon Police Department Lt. Pex.

21. *People v. Covino*, 100 Cal. App. 3d 660 (1980).

22. *People v. Kinsey*, 40 Cal. App. 4th 1621 (1995).

23. *Petechial Hemorrhages: A review of Pathogenesis*. The American Journal of Forensic Medicine and Pathology. 15:3, 1994, 203-2070. F. A. Jaffe.

24. *Laryngotracheal Trauma: Recognition and Management*. J AM Coll Emergency Phys A study of fatal strangulation cases in Varanasi (India). Am. Journal of Forensic Medicine anicians. 5:883-887, 1976, G.E. Lambert and G.T. McMurray.

25. *Deaths Allegedly Caused by the Use of "Choke Holds."* E. Karl Koiwai, M.D.

26. *State v. Carter*, 451 S.E.2d 157 (1994), [where expert testified manual strangulation would have taken four minutes for death to occur]; *State v. Bingham*, 719 P.2d 109 (1986) [three to five minutes]; and *People v. Rushing*, case no. SCD 114890 (1986), [court transcript where Deputy District Attorney Dan Goldstein elicited the following expert testimony from Dr. Christopher Swalwell: "The minimum amount of time to strangle somebody is somewhere around a minute to two for them to die, but obviously it could be longer."]

27. *Injuries of the Larynx and Cervical Trauma*. Ann Otol Rhino Larngo 80:419-422, 1971. G.S. Fitz-Hugh, W.M. Wallenborn and F. McGovern.